The Journal of Emergency Medicine, Vol. 62, No. 1, pp. 16–27, 2022
Published by Elsevier Inc.
0736-4679/$ - see front matter

https://doi.org/10.1016/j.jemermed.2021.09.015

Clinical Review

Diagnosis and Management of Cellulitis and Abscess in the Emergency Department Setting: An Evidence-Based Review

Brit Long, MD,* and Michael Gottlieb, MD†

*Department of Emergency Medicine, Brooke Army Medical Center, Houston, Texas, and †Department of Emergency Medicine, Rush University Medical Center, Chicago, Illinois
Reprint Address: Brit Long, MD, Department of Emergency Medicine, Brooke Army Medical Center, 3841 Roger Brooke Drive, Fort Sam Houston, TX 78234

☐ **Abstract—Background: Cellulitis and abscess are a common reason for presentation to the emergency department, although there are several nuances to the care of these patients. Objective: The purpose of this narrative review article was to provide a summary of the background, pathophysiology, diagnosis, and management of cellulitis and abscesses with a focus on emergency clinicians. Discussion: The most common bacteria causing cellulitis are *Staphylococcus aureus, Streptococcus pyogenes*, and other β-hemolytic streptococci, and methicillin-resistant *S. aureus* is most common in abscesses. The history and physical examination are helpful in differentiating cellulitis and abscess in many cases, and point-of-care ultrasound can be a useful tool in unclear cases. Treatment for cellulitis typically involves a penicillin or cephalosporin, and treatment of abscesses is incision and drainage. Loop drainage is preferred over the traditional incision and drainage technique, and adjunctive antibiotics can be considered. Most patients can be managed as outpatient. Conclusions: It is essential for emergency physicians to be aware of the current evidence regarding the diagnosis and management of patients with cellulitis and abscess. Published by Elsevier Inc.**

This review does not reflect the views or opinions of the U.S. government, Department of Defense, U.S. Army, U.S. Air Force, Brooke Army Medical Center, or San Antonio Uniformed Services Health Education Consortium Emergency Medicine Residency Program.

☐ **Keywords—abscess; cellulitis; skin; soft tissue; antibiotics; incision and drainage**

Clinical Scenarios

Clinical Scenario A

A 23-year-old female patient presents with right lateral thigh redness and pain. She is afebrile and not ill-appearing. On examination, the patient has focal erythema, induration, and focal pain without palpable fluctuance. The physician is uncertain whether this is an abscess or cellulitis and wonders whether there are any other tests that can help delineate this.

Clinical Scenario B

A 72-year-old male patient presents with concern for bilateral leg cellulitis. The symptoms began gradually, and the patient does not recall any preceding trauma or acute change in symptoms. On examination, the patient has bilateral lower extremity swelling, dark red discoloration, and weeping from the skin. There is no increased warmth. The physician wonders whether to start antibiotics.

Received: 1 June 2021; Final submission received: 4 August 2021;
Accepted: 11 September 2021

Introduction

Epidemiology

Skin and soft-tissue infections (SSTIs), including cellulitis and abscess, are common diagnoses in the emergency department (ED) setting. Although SSTIs include diseases ranging from uncomplicated cellulitis to necrotizing fasciitis, SSTIs are typically divided into nonpurulent (e.g., cellulitis and erysipelas) and purulent forms (e.g., folliculitis, furuncles, carbuncles, and abscesses) (1–6). Approximately 6 million patients present to the ED every year for cellulitis or abscess (3,7–9). The annual incidence of cellulitis ranges from 22 to 50 per 1000 persons, with more than 14 million cases in the United States every year (3,5–12). Fewer than 10% of patients with cellulitis require hospitalization (1,3,10). Among patients requiring hospitalization, the mortality rate is 2.5%. However, the rate of hospitalization and disease severity increase significantly after 55 years of age (1,10). The emergence of methicillin-resistant *Staphylococcus aureus* (MRSA) initially led to an increase in abscesses and purulent cellulitis, with ED visits for cellulitis and abscess increasing by 50% from 1997 to 2005 (7). However, since that time, ED visits for SSTIs have decreased, with one study reporting ED visits for cellulitis and abscess declining from 2009 to 2014 (11).

MRSA can be classified as either health care–associated MRSA (HA-MRSA) or community-acquired MRSA (CA-MRSA) (12–14). HA-MRSA is defined as a MRSA infection occurring more than 48 h after hospitalization or infection occurring within 12 months of health care exposure (1,13–17). Risk factors for HA-MRSA include prolonged hospitalization, prior MRSA colonization, intensive care unit admission, antibiotic use, hemodialysis, discharge to a nursing home, or presence of a chronic wound (18–28). CA-MRSA is an infection occurring with no health care exposure (1,18,29). CA-MRSA is more frequently associated with abscesses and purulent cellulitis in young, healthy patients, and has become increasingly prevalent since the 1990s (1,18,29). In fact, MRSA is the most common isolate among patients with uncomplicated abscesses and is significantly more common than methicillin-sensitive *S. aureus* (18).

Methods

This narrative review is focused on cellulitis and abscess, with an emphasis on the emergency physician. It will not review other soft-tissue infections, such as erysipelas, folliculitis, furuncle, impetigo, toxic shock syndrome, staphylococcal scalded skin syndrome, or necrotizing soft-tissue infection, which have been covered elsewhere (30,31). We searched PubMed and Google Scholar for articles using a combination of the keywords *abscess, cellulitis, skin*, and *soft tissue*. The literature search was restricted to studies published in English. When available, systematic reviews and meta-analyses were preferentially selected. These were followed sequentially by randomized controlled trials, prospective studies, retrospective studies, case reports, and other narrative reviews when alternate data were not available. We reviewed all relevant articles and decided by consensus which studies to include for the review. A total of 91 articles were selected for inclusion in this review.

Discussion

Microbiology and Pathology

The skin is comprised of several layers that form a barrier protecting the body from infection (1,3). Any disruption of the cutaneous barrier provides a site for normal skin flora and other bacteria to enter the dermis and subcutaneous layers of the skin, which can prompt an inflammatory response consisting of neutrophil recruitment and infiltration into the affected areas and cytokine production (1,3,4,32). In cases of nonpurulent cellulitis, a small number of bacteria and a robust inflammatory response most commonly result in a localized infection (1,3,4,32).

An abscess develops after the entry of bacteria into the skin layers, usually through a portal of entry such as a wound (1,33). However, if there is no obvious portal of entry, a hair follicle or minor damage to the keratinized epithelium can also provide a portal of entry. An inflammatory response occurs with recruitment of cytokines and neutrophils to the area, phagocytosis of bacteria, liquefactive necrosis, and edema (1,33). A fibrous capsule develops that surrounds the cell debris and necrotic neutrophils (33). This fibrous capsule of the abscess is often surrounded by erythema and induration. If this erythema and induration spread beyond the abscess margin, this is suggestive of purulent cellulitis. As the overlying tissue thins due to necrosis, spontaneous rupture of the abscess with drainage can occur.

A variety of bacterial pathogens can result in cellulitis or abscess. The most common microbe (> 70% of cases) causing nonpurulent cellulitis is β-hemolytic streptococci, which includes subtypes A, B, C, G, and F, although subtype A (*Streptococcus pyogenes*) is the most common (1,3,24,34–40). This is followed by *S. aureus*, which is found in 14–27% of cases (1,3,34,35,41). MRSA is present in only 4% of nonpurulent cellulitis cases (11,18,34,42,43). Gram-negative bacilli are rarely the predominant cause of cellulitis or abscess (1,3).

By comparison, *S. aureus* is the predominant microbe in abscesses, accounting for 60–75% of cases, with up to 70% of these being MRSA (1,3,18,43–50). β-Hemolytic streptococcal species account for < 5% of these infections (1,3). Of note, patients with injection drug use–related abscesses often have polymicrobial infections, which can include oral streptococci and anaerobic species (51).

MRSA possesses several unique attributes that increase its ability to cause infection (1,33). MRSA frequently colonizes the nares, oropharynx, rectum, groin, and axilla, increasing the risk of subsequent infection (52). MRSA also produces a biofilm on invasive devices, which can enhance microbial survival and reproduction. In addition, most CA-MRSA strains possess genes for production of the Panton-Valentine leucocidin cytotoxin, which increase the microbe's virulence (53–58).

History and Physical Examination

Patients should be asked about their initial symptoms, including when they began, how they have progressed, any medications used or interventions performed (e.g., prior attempts at incision and drainage), recent surgical procedures, and history of skin and soft-tissue infections (1,3,4,59). The history should also focus on factors that predispose the patient to infection, as well as symptoms and risk factors for more severe infections (e.g., fever, chills, and rigors) (1,3,4,59). Conditions associated with a greater risk of soft-tissue infection include injection of drugs and medications, impaired lymphatic drainage, prior episodes of cellulitis, disruption of the cutaneous barrier (e.g., ulcer and wounds), poor hygiene, obesity, edema, and lower extremity venous insufficiency (1,3,4,33,32,59). Immunocompromising states can increase the risk of infection and progression to more severe disease. These include diabetes, cirrhosis, end-stage renal disease, neutropenia, human immunodeficiency virus infection, and use of immunosuppressive medications (1,3,4).

The physical examination should include a thorough inspection of the affected area, as well as evaluation for a portal of entry of infection (e.g., skin ulcer) and mimics of cellulitis and abscess. Patients with cellulitis will typically present with pain, warmth, edema, tenderness, and erythema (1,3–5,59). Erythema and induration may have poor demarcation and will typically develop over several days (Figure 1). The lower extremities are the most common location affected, and limb involvement can be circumferential (1,3–5,59). If the lower extremity is involved, the interspaces of the toes should be evaluated for evidence of a fungal infection, which can be a precipitating cause in approximately 50% of cases (1,3–5,59). Alternatively, an abscess will present as a fluctuant, pyogenic focus with a surrounding rim of erythema. Spontaneous drainage of purulent material can occur as the abscess extends towards the skin surface (Figure 2) (1,3–5,59). Lymphangitis, which occurs when the infection extends to the lymphatic system, will present as erythema overlying the lymphatic system, extending towards lymph nodes. Of note, systemic symptoms, including malaise, fevers, and fatigue, can also occur in those with cellulitis and abscess.

Figure 1. Cellulitis of the left lower extremity. From https://www.flickr.com/photos/104346167@N06/44699141152/in/photostream/

Figure 2. Abscess of the upper leg with spontaneous drainage. From https://commons.wikimedia.org/wiki/File:Cutaneous_abscess_MRSA_staphylococcus_aureus_7826_lores.jpg

Differential Diagnosis

Cellulitis can be challenging to differentiate from other conditions (Table 1) and has high rates of misdiagnosis; therefore, several studies have sought to differentiate cellulitis from these mimics (18,59–65). One common differentiating factor is that cellulitis is typically acute and

Table 1. Cellulitis and Abscess Mimics (59–61)

Condition	Consideration
Calciphylaxis	Metastatic calcifications and small-vessel vasculopathy that presents with nonulcerating plaques in the early stages, followed by necrotic and painful ulcer development; predominantly affects patients with diabetes with renal disease and hyperparathyroidism
Compartment syndrome	Increased pressure within an enclosed fascial space; typically occurs with trauma and affects anterior tibial compartment; can present with redness and severe pain
Contact dermatitis	Pruritic with well-defined borders; usually has a history of irritant exposure
Deep venous thrombosis	Unilateral swelling with deep pain, typically in the calf; may have redness; fever may be present but rarely $> 38.3°C$
Drug rash	Fixed drug reaction appearing as a pruritic, burning, well-demarcated plaque that occurs after administration of offending drug; may heal with residual hyperpigmentation
DRESS	Adverse drug reaction with fever and maculopapular rash; may have vesicles or bullae and lymphadenopathy; usually has systemic symptoms; can also have eosinophilia, leukocytosis, thrombocytopenia, and anemia
Eosinophilic cellulitis	Acute pruritic dermatitis with several erythematous plaques evolving over 2–3 days and resolving within 2–8 weeks; characterized by eosinophilic infiltration in the affected sites
Erythema ab igne	Dermatosis with erythema and pigmentation after heat or infrared radiation exposure
Erythema migrans	Manifestation of Lyme disease; round plaque, well-demarcated, painless, slowly progressive, often with central clearing
Erythema multiforme	Acute and self-limited with erythematous or violaceous macules, papules, vesicles, or bullae; may have target lesions; usually symmetric distribution
Erythema nodosum	Raised, bilateral, painful, and tender lesions most commonly over the shins; lesions may coalesce into a single lesion; resolves within 4–6 weeks
Erythromelalgia	Episodic burning, increased temperature of the skin, bilateral extremity redness; most commonly affects the feet, followed by the hands; no symptoms between episodes
Gout	Inflammation over a joint with warmth and erythema; may extend past joint and present with chills or a low-grade fever
Herpes zoster	Dermatomal distribution; pain and erythema typically precede vesicle development
Impetigo	Superficial infection of the epidermis with amber crusts or vesicles; usually no systemic symptoms
Insect bite/sting	Reactions range from localized redness that may worsen over 2–7 days to anaphylaxis with airway obstruction
Lipodermatosclerosis	Fibrosing panniculitis of subcutaneous tissue; painful with poor demarcation; starts medial to the ankle, often red or purple when acute
Lymphedema	Abnormal accumulation of interstitial fluid with nonpitting edema and erythema; not warm; hyperkeratosis; hyperpigmentation; nodules
Malignancy	Lymphoma and leukemia may present with skin lesions and systemic symptoms, such as fever, generalized lymphadenopathy, or night sweats
Necrotizing fasciitis	Deep infection with destruction of tissue, including muscle fascia; presents with erythema, swelling, warmth, severe tenderness, and rapid progression

(*continued on next page*)

Table 1. (*continued*)

Condition	Consideration
Phlegmasia alba dolens	Iliofemoral occlusion due to deep venous thrombosis that spares collateral veins; presents with pain, edema, white appearance
Phlegmasia cerulea dolens	Iliofemoral occlusion due to deep venous thrombosis with venous congestion, sudden/severe pain, cyanosis
Pyoderma gangrenosum	Dysfunction of neutrophils; begins with small red papule or pustule that changes into large, painful ulcers with undermining and well-defined borders
Sarcoidosis	Characteristic granulomas; indurated erythematous plaques with pain and edema; often with associated lung involvement, uveitis, lymphadenopathy
Septic arthritis or bursitis	Erythema and swelling over joint or bursa; joint or bursa tenderness; fever
SJS and TEN	SJS involves < 10% of the BSA and TEN involves > 30% of the BSA; prodrome followed by macular rash and mucous membrane involvement
Sweet syndrome	Acute febrile neutrophilic dermatosis with papules that coalesce into inflammatory plaques with fever, conjunctivitis or iridocyclitis, oral aphthae, and arthralgia or arthritis; lesions are tender and erythematous
Thrombophlebitis	Erythema, induration, tender and palpable cord along superficial vein
Toxic shock syndrome	Severe pain, local swelling, erythema, nausea, vomiting, fever, hypotension, and tachycardia
Vasculitis	Includes several diseases, such as lupus erythematosus, polyarteritis nodosa, and localized scleroderma; variable morphology of skin lesions but typically macular and papular without blanching
Venous stasis	Chronic venous insufficiency resulting in redness, superficial desquamation, weeping or crusting, pitting edema; typically bilateral; may result in a stasis ulcer in severe disease
Urticaria	Presents with raised, pruritic lesions that change in size and location; typically has a precipitating factor

BSA = body surface area; DRESS = drug reaction with eosinophilia and systemic symptoms; SJS = Stevens-Johnson syndrome; TEN = toxic epidermal necrolysis.

unilateral; involvement of both lower extremities usually suggests another condition (59–61). Erythema associated with cellulitis also does not typically resolve with limb elevation (59). The mnemonic CELLULITIS can assist (see Table 2). One meta-analysis found previous cellulitis (odds ratio [OR] 40.3), presence of a wound on the leg (OR 19.1), current leg ulcer (OR 13.7), lymphedema or chronic leg edema (OR 6.8), excoriating skin disease (OR 4.4), tinea pedis (OR 3.2), and body mass index > 30 kgm^2 (OR 2.4) to be associated with increased risk of developing nonpurulent cellulitis of the leg (28,64). Pain out of proportion to examination, bullae, vesicles, and crepitus are suggestive of a necrotizing soft-tissue infection, and erythema overlying a joint in a patient with painful range of motion or pain with axial loading suggests septic arthritis (59). Severe pain, significant edema, and skin discoloration of the entire extremity (e.g., white or blue) suggest phlegmasia alba dolens or cerulea dolens (59).

Laboratory Testing

Laboratory testing and cultures are of limited utility in this population. If obtained, the white blood cell count is typically elevated in 34–50% of cases (6,56). The erythrocyte sedimentation rate is elevated in 50–91% of cases, and C-reactive protein is elevated in 77–97% of cases (6,56). Procalcitonin has been proposed as a potential biomarker to distinguish cellulitis from mimics (e.g., deep venous thrombosis and venous stasis). However, one study found that procalcitonin was only 58% sensitive and 82% specific (66).

Table 2. Factors Suggestive of Cellulitis (64)

Factor	Considerations
CELLULITIS	
Cellulitis history	Present in more than half of cases, with an odds ratio of 31–40.3.
Edema	Swelling (lymphedema or venous edema), pain, erythema, and warmth increase the risk. Lymphedema is the most significant factor of these four.
Local warmth	The site is warmer than areas on the opposite extremity; a difference of $> 0.5°C$ demonstrates high accuracy.
Lymphangitis	Ascending lymphangitis is specific, but not sensitive.
Unilateral	Cellulitis should be asymmetrical and unilateral; bilateral involvement is more common with venous stasis.
Leukocytosis	White blood cell count $>$ 10,000 is suggestive in older patients.
Injury	Damage or injury to the skin increases the risk of cellulitis.
Tender	Cellulitis more commonly presents as tenderness with palpation, rather than pain at rest.
Instant onset	The patient typically recalls the day of sudden worsening, compared with venous stasis which is chronic.
Systemic signs	Tachycardia and other systemic signs (e.g., fever) suggest cellulitis.

Routine blood cultures are generally low yield and not recommended by the Infectious Diseases Society of America (IDSA) (1). One meta-analysis reported that only 7.9% of blood cultures among patients with cellulitis were positive, with most comprising *S. aureus, S. pyogenes*, or other β-hemolytic streptococci (67). However, blood cultures can be useful in patients with significant systemic symptoms who are at greater risk for atypical organisms (e.g., immunocompromise, exposure to aquatic injuries, and animal bites) and those patients with concern for sepsis and bacteremia associated with soft-tissue infection (1,3,67). The IDSA also does not currently recommend obtaining routine skin swabs of cellulitis or infected ulcers (1). Alternatively, the IDSA does recommend obtaining a culture of the purulent fluid in patients with abscesses (1). However, as MRSA is the predominant cause of abscess, culture of purulent material from an abscess is unlikely to change management.

Imaging

Plain radiographs have little role in the evaluation of cellulitis and abscesses. Although radiographs can identify bone abnormalities in osteomyelitis or soft-tissue air in necrotizing fasciitis, they are neither sensitive nor specific (68). Therefore, if these diagnoses are being considered, alternate testing modalities should be used (e.g., computed tomography and magnetic resonance imaging) (1,31,69).

Point-of-care ultrasound (POCUS) is a valuable adjunct for differentiating cellulitis from abscess. A recent meta-analysis demonstrated that POCUS was 94.6% sensitive and 85.4% specific overall (70). Moreover, the authors found that POCUS led to a correct change in management in 10.3% of cases and an incorrect change in management in 0.7% of cases (70). POCUS is particularly valuable in clinically unclear cases, where it significantly outperforms physical examination alone (70–74). Among clinically apparent cases, POCUS is less likely to influence management (73). However, POCUS can be valuable for identifying the preferred location to perform the incision and drainage, as well as avoiding the incision of pseudoaneurysms, which will display flow on Doppler imaging (74,75). Figure 3 demonstrates a cobblestone appearance consistent with cellulitis on POCUS, which occurs due to the presence of subcutaneous fluid separating hyperechoic fat lobules. Figure 4 demonstrates a hypoechoic fluid collection consistent with abscess.

Computed tomography (CT) is another option when evaluating for the presence of abscesses. This can be of particular use when evaluating deeper-space abscesses (1,59,69). However, CT can miss smaller abscesses, with one study reporting that CT was 76.7% sensitive and 91.4% specific (76).

Treatment

Antibiotics

The treatment of choice for cellulitis is antibiotics. Despite the increasing prevalence of MRSA among abscesses, most cases of uncomplicated cellulitis can still be treated with more narrow-spectrum antibiotics. One

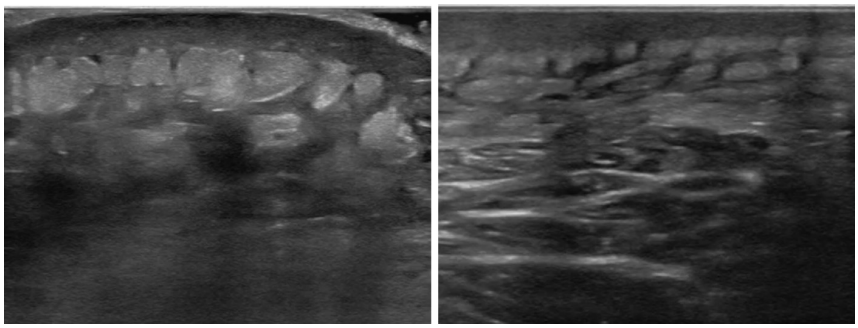

Figure 3. Point-of-care ultrasound demonstrating a cobblestone appearance consistent with cellulitis.

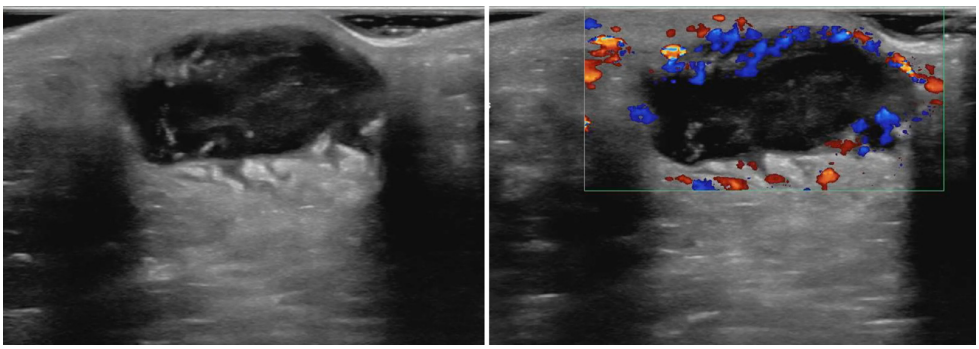

Figure 4. Point-of-care ultrasound demonstrating a fluid collection. The image on the right demonstrates surrounding hyperemia with no Doppler flow within the fluid cavity.

randomized controlled trial found that the addition of trimethoprim-sulfamethoxazole to cephalexin for cellulitis did not significantly improve the rate of resolution (40). Another study found that adding clindamycin to flucloxacillin did not improve outcomes and doubled the risk of antibiotic-associated diarrhea (77). Therefore, the IDSA recommends most cases of nonpurulent cellulitis be treated with penicillin VK, a cephalosporin, dicloxacillin, or clindamycin (1). However, when purulent cellulitis is present (i.e., cellulitis in the presence of a pustule, abscess, or purulent drainage), MRSA is much more likely, and an antibiotic with activity against MRSA should be selected (e.g., trimethoprim-sulfamethoxazole, doxycycline) (1,18,75,78). Specific antibiotic choices should be guided by local resistance patterns and antibiograms (1,3). Treatment typically ranges from 5 to 10 days, although immunocompromised patients might require a longer course (7–14 days) (1). One study found that a 5-day course was as effective as longer courses, so physicians can consider prescribing a 5-day course with the option of a second 5-day course if symptoms do not improve significantly (79).

Although antibiotics are commonly prescribed for cellulitis, their role in abscess management is less clear (75,78). One large systematic review and meta-analysis of 2406 patients found that adjunctive antibiotics reduced treatment failure by half (16.1% vs. 7.7%) (80). The authors also found that there was a statistically significant reduction in new lesion formation (15.3% vs. 6.2%) (80). However, this must be balanced against the risk of adverse events and the potential for antimicrobial resistance. In the aforementioned systematic review, there was an increase in adverse events with antibiotics (24.8% vs. 22.2%), but most were mild and there was no difference in the incidence of *Clostridium difficile* (80). We recommend antibiotics with MRSA coverage for those with cellulitis overlying the abscess. Patient preference and local resistance patterns must be considered with shared decision making when considering antibiotics for uncomplicated abscesses.

Incision and drainage

The treatment of choice for skin and soft-tissue abscesses is incision and drainage (78). Although needle drainage has been described, one study found that providers were successful in obtaining purulent material in only 40% of cases with needle drainage, despite visualization on ultrasound, compared to 96% with standard incision and drainage (76). Moreover, abscesses that were aspirated had significantly worse outcomes, defined as sonographic resolution of abscess on days 0 and 2, im-

provement of clinical symptoms on day 2, and resolution of clinical symptoms on day 7, compared with standard incision and drainage (overall 74% failure rate with needle drainage vs. 20% failure rate with incision and drainage) (76).

When making the initial incision, providers should attempt to follow the Langer's lines of the skin to reduce the tension on the wound during healing and improve the cosmetic appearance after it has healed (78). POCUS can also be useful to identify the margins of the wound and assess the dimensions of the abscess and ideal location for the incision.

One study evaluated the role of irrigation and found no difference in cure rates with or without irrigation (81). In addition, irrigation can lead to longer procedure time, increased pain, and greater risk of microbiologic contamination to the provider (78). Therefore, irrigation is not recommended for routine management at this time (75).

Packing is more controversial. One study of 48 adult patients compared packing with open drainage and found no difference in treatment failure (82). However, the packing group reported higher pain scores and greater use of opioid medications (82). Another study of 57 pediatric patients also found no difference in failure rates (83). Unfortunately, both of these were pilot studies and underpowered to identify differences in outcomes. As such, it may be reasonable to refrain from packing small abscesses (e.g., < 5 cm in diameter), but more data are needed to determine the impact on larger abscesses (75,82). It is reasonable to withhold packing, provided the patient has strict return precautions for evidence of worsening infection.

The loop drainage technique is a newer approach, wherein the provider makes two small incisions at opposite margins of the abscess. The clinician then breaks up loculations with a hemostat, followed by placement of a vessel loop through the abscess (75,84–87). The ends are then tied over the abscess to create a loop (Figure 5). Patients can then slide the loop back-and-forth each day to promote drainage and the loop can be easily cut and removed once the abscess has begun to resolve. A modification of this technique has also been described using the rubber loop from a sterile surgical glove (84). When compared with standard incision and drainage, the loop technique has a significantly lower failure rate (8.3% vs. 14.2%) (86). One study suggests the loop technique is also less painful and preferred by patients (87).

Symptomatic management

Patients should be advised to keep the affected extremity elevated when possible to assist with venous drainage and swelling, which can reduce some of the associated discomfort. Nonsteroidal anti-inflammatory drugs (NSAIDs) have also been proposed to reduce inflammation and pain. One study randomized patients with cellulitis to receive NSAIDs (ibuprofen 400 mg every 6 h for 10 days) with antibiotics vs. antibiotics alone and reported faster resolution of symptoms in the NSAID group (88). Another randomized, placebo-controlled trial assessing NSAIDS (ibuprofen 400 mg three times daily for 5 days) found a non–statistically significant increase in resolution of symptoms (80% vs. 65%) (89). The data for steroids are more limited. One randomized, placebo-controlled trial of prednisolone among admitted patients reported shorter hospital stay and fewer days of intravenous antibiotic therapy in the prednisolone group, with no difference in adverse effects or relapse within 1 year (90,91). However, the authors excluded patients with diabetes mellitus or peptic ulcer disease, so it is important to exercise caution in those at higher risk of adverse events. Based on the available data, we recommend NSAIDs if not contraindicated based on patient comorbidities (e.g., renal disease or peptic ulcer disease), but we do not recommend routine use of steroids.

Figure 5. Loop drainage of an abscess. Courtesy of Dr. David Thompson.

Disposition

Most cases of cellulitis or abscess can be managed as outpatient (1,3,4). Patients should be advised to follow up with their primary care physician or in the ED for reevaluation if the symptoms are not beginning to improve within the first 48–72 h. Although the data are limited, it is often recommended that patients should soak the abscess cavity in soapy water to enhance drainage (75). Patients with cellulitis that does not improve with outpatient antibiotics might benefit from admission for intravenous antibiotics. Patients with sepsis should be admitted to the

hospital, and those with septic shock might require a critical care setting (1).

Conclusions

Skin and soft-tissue infections are a common presentation in the ED. The most common etiologic agents in cellulitis are *S. aureus, S. pyogenes*, or other β-hemolytic streptococci, and MRSA is most common in abscesses. The history and physical examination are helpful in delineating cellulitis and abscess in many cases, and POCUS is a useful tool in unclear cases. Treatment for cellulitis typically involves a penicillin or cephalosporin, and abscesses are treated with incision and drainage. Most patients can be managed as outpatient. It is essential for emergency physicians to be aware of the current evaluation and management of cellulitis and abscesses.

Clinical Bottom Line

Clinical Scenario A

The physician performs a POCUS and identifies a hypoechoic area with surrounding hyperemia suggestive of an abscess. The physician then incises the abscess and places a loop drain.

Clinical Scenario B

The physician notes bilateral cellulitis is exceedingly rare. The gradual onset, lack of increased warmth, and evidence of venous stasis (hyperpigmentation and skin weeping) make cellulitis significantly less likely. The physician provides strategies for improving venous return and close follow-up for re-evaluation.

REFERENCES

1. Stevens DL, Bisno AL, Chambers HF, et al. Practice guidelines for the diagnosis and management of skin and soft tissue infections: 2014 update by the Infectious Diseases Society of America. Clin Infect Dis 2014;59(2):e10–52.
2. Brown BD, Hood Watson KL. Cellulitis. StatPearls Publishing; 2021.
3. Raff AB, Kroshinsky D. Cellulitis: a review. JAMA 2016;316:325–37.
4. Cranendonk DR, Lavrijsen APM, Prins JM, Wiersinga WJ. Cellulitis: current insights into pathophysiology and clinical management. Neth J Med 2017;75:366–78.
5. Morris A. Cellulitis and erysipelas. Clin Evid 2006(15):2207–11.
6. Lazzarini L, Conti E, Tositti G, de Lalla F. Erysipelas and cellulitis: clinical and microbiological spectrum in an Italian tertiary care hospital. J Infect 2005;51:383–9.
7. Hersh AL, Chambers HF, Maselli JH, Gonzales R. National trends in ambulatory visits and antibiotic prescribing for skin and soft-tissue infections. Arch Intern Med 2008;168:1585–91.
8. Miller LG, Daum RS, Creech CB, et al. Clindamycin versus trimethoprim-sulfamethoxazole for uncomplicated skin infections. N Engl J Med 2015;372:1093–103.
9. McNamara DR, Tleyjeh IM, Berbari EF, et al. Incidence of lower-extremity cellulitis: a population-based study in Olmsted county, Minnesota. Mayo Clin. Proc 2007;82:817–21.
10. Goettsch WG, Bouwes Bavinck JN, Herings RM. Burden of illness of bacterial cellulitis and erysipelas of the leg in the Netherlands. J Eur Acad Dermatol Venereol 2006;20:834–9.
11. Morgan E, Hohmann S, Ridgway JP, et al. Decreasing incidence of skin and soft-tissue infections in 86 US emergency departments, 2009-2014. Clin Infect Dis 2019;68:453–9.
12. National Nosocomial Infections Surveillance SystemNational Nosocomial Infections Surveillance (NNIS) System Report, data summary from January 1992 through June 2004, issued October 2004. Am J Infect Control 2004;32:470–85.
13. Klevens RM, Morrison MA, Nadle J, et al. Active Bacterial Core surveillance (ABCs) MRSA Investigators. Invasive methicillin-resistant *Staphylococcus aureus* infections in the United States. JAMA 2007;298:1763–71.
14. Wisplinghoff H, Bischoff T, Tallent SM, et al. Nosocomial bloodstream infections in US hospitals: analysis of 24,179 cases from a prospective nationwide surveillance study. Clin Infect Dis 2004;39:309–17.
15. Boyce JM. Methicillin-resistant *Staphylococcus aureus* in hospitals and long-term care facilities: microbiology, epidemiology, and preventive measures. Infect Control Hosp Epidemiol 1992;13:725–37.
16. Klevens RM, Edwards JR, Tenover FC, et al. National Nosocomial Infections Surveillance System. Changes in the epidemiology of methicillin-resistant *Staphylococcus aureus* in intensive care units in US hospitals, 1992-2003. Clin Infect Dis 2006;42:389–91.
17. Cosgrove SE, Sakoulas G, Perencevich EN, et al. Comparison of mortality associated with methicillin-resistant and methicillin-susceptible *Staphylococcus aureus* bacteremia: a meta-analysis. Clin Infect Dis 2003;36:53–9.
18. Moran GJ, Krishnadasan A, Gorwitz RJ, et al. Methicillin-resistant *S. aureus* infections among patients in the emergency department. N Engl J Med 2006;355:666–74.
19. McNamara DR, Tleyjeh IM, Berbari EF, et al. A predictive model of recurrent lower extremity cellulitis in a population-based cohort. Arch Intern Med 2007;167:709–15.
20. Dan M, Heller K, Shapira I, et al. Incidence of erysipelas following venectomy for coronary artery bypass surgery. Infection 1987;15:107–8.
21. Baddour LM, Bisno AL. Recurrent cellulitis after saphenous venectomy for coronary bypass surgery. Ann Intern Med 1982;97:493–6.
22. Baddour LM. Breast cellulitis complicating breast conservation therapy. J Intern Med 1999;245:5–9.
23. Dankert J, Bouma J. Recurrent acute leg cellulitis after hysterectomy with pelvic lymphadenectomy. Br J Obstet Gynaecol 1987;94:788–90.
24. Semel JD, Goldin H. Association of athlete's foot with cellulitis of the lower extremities: diagnostic value of bacterial cultures of ipsilateral interdigital space samples. Clin Infect Dis 1996;23:1162–1164.
25. Gordon RJ, Lowy FD. Bacterial infections in drug users. N Engl J Med 2005;353:1945–54.
26. Begier EM, Frenette K, Barrett NL, et al. Connecticut Bioterrorism Field Epidemiology Response Team. A high-morbidity outbreak of

methicillin-resistant *Staphylococcus aureus* among players on a college football team, facilitated by cosmetic body shaving and turf burns. Clin Infect Dis 2004;39:1446–53.
27. Hilmarsdóttir I, Valsdóttir F. Molecular typing of beta-hemolytic streptococci from two patients with lower-limb cellulitis: identical isolates from toe web and blood specimens. J Clin Microbiol 2007;45:3131–2.
28. Quirke M, Ayoub F, McCabe A, et al. Risk factors for nonpurulent leg cellulitis: a systematic review and meta-analysis. Br J Dermatol 2017;177:382–94.
29. Fridkin SK, Hageman JC, Morrison M, et al. Active Bacterial Core Surveillance Program of the Emerging Infections Program Network. Methicillin-resistant *Staphylococcus aureus* disease in three communities. N Engl J Med 2005;352:1436–44.
30. Gottlieb M, Long B, Koyfman A. The evaluation and management of toxic shock syndrome in the emergency department: a review of the literature. J Emerg Med 2018;54:807–14.
31. Auerbach J, Bornstein K, Ramzy M, Cabrera J, Montrief T, Long B. Fournier gangrene in the emergency department: diagnostic dilemmas, treatments and current perspectives. Open Access Emerg Med 2020;12:353–64.
32. Raff AB, Weng QY, Cohen JM, et al. A predictive model for diagnosis of lower extremity cellulitis: a cross-sectional study. J Am Acad Dermatol 2017;76:618–25 e2.
33. Kobayashi SD, Malachowa N, DeLeo FR. Pathogenesis of *Staphylococcus aureus* abscesses. Am J Pathol 2015;185:1518–27.
34. Jeng A, Beheshti M, Li J, Nathan R. The role of beta-hemolytic streptococci in causing diffuse, nonculturable cellulitis: a prospective investigation. Medicine (Baltimore) 2010;89:217–26.
35. Bruun T, Oppegaard O, Kittang BR, et al. Etiology of cellulitis and clinical prediction of streptococcal disease: a prospective study. Open Forum Infect Dis 2015;3:ofv181.
36. Bernard P, Bedane C, Mounier M, et al. Streptococcal cause of erysipelas and cellulitis in adults. A microbiologic study using a direct immunofluorescence technique. Arch Dermatol 1989;125:779–82.
37. Leppard BJ, Seal DV, Colman G, Hallas G. The value of bacteriology and serology in the diagnosis of cellulitis and erysipelas. Br J Dermatol 1985;112:559–67.
38. Björnsdóttir S, Gottfredsson M, Thórisdóttir AS, et al. Risk factors for acute cellulitis of the lower limb: a prospective case-control study. Clin Infect Dis 2005;41:1416–22.
39. Carratalà J, Rosón B, Fernández-Sabé N, et al. Factors associated with complications and mortality in adult patients hospitalized for infectious cellulitis. Eur J Clin Microbiol Infect Dis 2003;22:151–7.
40. Siljander T, Karppelin M, Vähäkuopus S, et al. Acute bacterial, nonnecrotizing cellulitis in Finland: microbiological findings. Clin Infect Dis 2008;46:855–61.
41. Gonzales y Tucker RD, Frazee B. View from the front lines: an emergency medicine perspective on clostridial infections in injection drug users. Anaerobe 2014;30:108–15.
42. Pallin DJ, Binder WD, Allen MB, et al. Clinical trial: comparative effectiveness of cephalexin plus trimethoprim-sulfamethoxazole versus cephalexin alone for treatment of uncomplicated cellulitis: a randomized controlled trial. Clin Infect Dis 2013;56:1754–62.
43. Talan DA, Krishnadasan A, Gorwitz RJ, et al. Comparison of *Staphylococcus aureus* from skin and soft-tissue infections in US emergency department patients, 2004 and 2008. Clin Infect Dis 2011;53:144–9.
44. Talan DA, Mower WR, Krishnadasan A, et al. Trimethoprim-sulfamethoxazole versus placebo for uncomplicated skin abscess. N Engl J Med 2016;374:823–32.
45. Daum RS, Miller LG, Immergluck L, et al. A placebo-controlled trial of antibiotics for smaller skin abscesses. N Engl J Med 2017;376:2545–55.
46. Singer AJ, Talan DA. Management of skin abscesses in the era of methicillin-resistant *Staphylococcus aureus*. N Engl J Med 2014;370:1039–47.
47. Summanen PH, Talan DA, Strong C, et al. Bacteriology of skin and soft-tissue infections: comparison of infections in intravenous drug users and individuals with no history of intravenous drug use. Clin Infect Dis 1995;20(2):S279–82 suppl.
48. Rajendran PM, Young D, Maurer T, et al. Randomized, double-blind, placebo-controlled trial of cephalexin for treatment of uncomplicated skin abscesses in a population at risk for community-acquired methicillin-resistant *Staphylococcus aureus* infection. Antimicrob Agents Chemother 2007;51:4044–8.
49. Ruhe JJ, Smith N, Bradsher RW, Menon A. Community-onset methicillin-resistant *Staphylococcus aureus* skin and soft-tissue infections: impact of antimicrobial therapy on outcome. Clin Infect Dis 2007;44:777–84.
50. Demos M, McLeod MP, Nouri K. Recurrent furunculosis: a review of the literature. Br J Dermatol 2012;167:725–32.
51. Jenkins TC, Knepper BC, Jason Moore S, et al. Microbiology and initial antibiotic therapy for injection drug users and non-injection drug users with cutaneous abscesses in the era of community-associated methicillin-resistant *Staphylococcus aureus*. Acad Emerg Med 2015;22:993–7.
52. Creech CB, Al-Zubeidi DN, Fritz SA. Prevention of recurrent staphylococcal skin infections. Infect Dis Clin North Am 2015;29:429–64.
53. Diep BA, Gill SR, Chang RF, et al. Complete genome sequence of USA300, an epidemic clone of community-acquired methicillin-resistant Staphylococcus aureus. Lancet 2006;367(9512):731–9.
54. Baba T, Takeuchi F, Kuroda M, et al. Genome and virulence determinants of high virulence community-acquired MRSA. Lancet 2002;359(9320):1819–27.
55. Diep BA, Carleton HA, Chang RF, et al. Roles of 34 virulence genes in the evolution of hospital- and community-associated strains of methicillin-resistant *Staphylococcus aureus*. J Infect Dis 2006;193:1495–503.
56. Ma XX, Ito T, Tiensasitorn C, Jamklang M, et al. Novel type of staphylococcal cassette chromosome mec identified in community-acquired methicillin-resistant *Staphylococcus aureus* strains. Antimicrob Agents Chemother 2002;46:1147–52.
57. Tenover FC, McDougal LK, Goering RV, et al. Characterization of a strain of community-associated methicillin-resistant *Staphylococcus aureus* widely disseminated in the United States. J Clin Microbiol 2006;44:108–18.
58. King MD, Humphrey BJ, Wang YF, et al. Emergence of community-acquired methicillin-resistant *Staphylococcus aureus* USA 300 clone as the predominant cause of skin and soft-tissue infections. Ann Intern Med 2006;144:309–17.
59. Blumberg G, Long B, Koyfman A. Clinical mimics: an emergency medicine-focused review of cellulitis mimics. J Emerg Med 2017;53:475–84.
60. Falagas ME, Vergidis PI. Narrative review: diseases that masquerade as infectious cellulitis. Ann Intern Med 2005;142:47–55.
61. Patel M, Lee SI, Thomas KS, Kai J. The red leg dilemma: a scoping review of the challenges of diagnosing lower-limb cellulitis. Br J Dermatol 2019;180:993–1000.
62. Weng QY, Raff AB, Cohen JM, et al. Costs and consequences associated with misdiagnosed lower extremity cellulitis. JAMA Dermatol 2017;153:141–6.
63. Moran GJ, Krishnadasan A, Mower WR, et al. Effect of cephalexin plus trimethoprim-sulfamethoxazole vs cephalexin alone on clinical

cure of uncomplicated cellulitis: a randomized clinical trial. JAMA 2017;317:2088–96.
64. Neill BC, Stoecker WV, Hassouneh R, et al. Cellulitis: a mnemonic to increase accuracy of cellulitis diagnosis. Dermatol Online J 2019;25(1) 13030/qt9mt4b2kc.
65. Krasagakis K, Valachis A, Maniatakis P, et al. Analysis of epidemiology, clinical features and management of erysipelas. Int J Dermatol 2010;49:1012–17.
66. Rast AC, Knobel D, Faessler L, et al. Use of procalcitonin, C-reactive protein and white blood cell count to distinguish between lower limb erysipelas and deep vein thrombosis in the emergency department: a prospective observational study. J Dermatol 2015;42:775–8.
67. Gunderson CG, Martinello RA. A systematic review of bacteremias in cellulitis and erysipelas. J Infect 2012;64:148–55.
68. Llewellyn A, Kraft J, Holton C, et al. Imaging for detection of osteomyelitis in people with diabetic foot ulcers: a systematic review and meta-analysis. Eur J Radiol 2020;131.
69. Gaspari R, Dayno M, Briones J, Blehar D. Comparison of computerized tomography and ultrasound for diagnosing soft tissue abscesses. Crit Ultrasound J 2012;4(1):5.
70. Gottlieb M, Avila J, Chottiner M, Peksa GD. Point-of-care ultrasonography for the diagnosis of skin and soft tissue abscesses: a systematic review and meta-analysis. Ann Emerg Med 2020;76(1):67–77. doi:10.1016/j.annemergmed.2020.01.004.
71. Berger T, Garrido F, Green J, et al. Bedside ultrasound performed by novices for the detection of abscess in ED patients with soft tissue infections. Am J Emerg Med 2012;30:1569–73.
72. Marin JR, Dean AJ, Bilker WB, et al. Emergency ultrasound assisted examination of skin and soft tissue infections in the pediatric emergency department. Acad Emerg Med 2013;20:545–53.
73. Gottlieb M, Sundaram T, Kim DJ, Olszynski P. Just the facts: point-of-care ultrasound for skin and soft-tissue abscesses. CJEM 2021;23:597–600. doi:10.1007/s43678-021-00132-9.
74. Alerhand S, Cherneykina M, Wei HS, Barricella RL. Point-of-care ultrasound diagnosis of medial plantar artery pseudoaneurysm secondary to penetrating injury. J Emerg Med 2020;58:781–4.
75. Schmitz GR, Gottlieb M. Managing a cutaneous abscess in the emergency department. Ann Emerg Med 2021;78:44–8.
76. Gaspari RJ, Resop D, Mendoza M, et al. A randomized controlled trial of incision and drainage versus ultrasonographically guided needle aspiration for skin abscesses and the effect of methicillin-resistant *Staphylococcus aureus*. Ann Emerg Med 2011;57:483–491.
77. Brindle R, Williams OM, Davies P, et al. Adjunctive clindamycin for cellulitis: a clinical trial comparing flucloxacillin with or without clindamycin for the treatment of limb cellulitis. BMJ Open 2017;7(3).
78. Gottlieb M, Schmitz G, Grock A, Mason J. What to do after you cut: recommendations for abscess management in the emergency setting. Ann Emerg Med 2018;71:31–3.
79. Hepburn MJ, Dooley DP, Skidmore PJ, et al. Comparison of short–course (5 days) and standard (10 days) treatment for uncomplicated cellulitis. Arch Intern Med 2004;164:1669–74.
80. Gottlieb M, DeMott JM, Hallock M, Peksa GD. Systemic antibiotics for the treatment of skin and soft tissue abscesses: a systematic review and meta-analysis. Ann Emerg Med 2019;73:8–16.
81. Chinnock B, Hendey GW. Irrigation of cutaneous abscesses does not improve treatment success. Ann Emerg Med 2016;67:379–83.
82. O'Malley GF, Dominici P, Giraldo P, et al. Routine packing of simple cutaneous abscesses is painful and probably unnecessary. Acad Emerg Med 2009;16:470–3.
83. Kessler DO, Krantz A, Mojica M. Randomized trial comparing wound packing to no wound packing following incision and drainage of superficial skin abscesses in the pediatric emergency department. Pediatr Emerg Care 2012;28:514–17.
84. Thompson DO. Loop drainage of cutaneous abscesses using a modified sterile glove: a promising technique. J Emerg Med 2014;47:188–91.
85. Gottlieb M, Peksa GD. Comparison of the loop technique with incision and drainage for soft tissue abscesses: a systematic review and meta-analysis. Am J Emerg Med 2018;36:128–33.
86. Gottlieb M, Schmitz G, Peksa GD. Comparison of the loop technique with incision and drainage for skin and soft tissue abscesses: a systematic review and meta-analysis. Acad Emerg Med 2021;28:346–54.
87. Özturan İU, Doğan NÖ, Karakayalı O, et al. Comparison of loop and primary incision & drainage techniques in adult patients with cutaneous abscess: a preliminary, randomized clinical trial. Am J Emerg Med 2017;35:830–4.
88. Dall L, Peterson S, Simmons T, Dall A. Rapid resolution of cellulitis in patients managed with combination antibiotic and anti-inflammatory therapy. Cutis 2005;75:177–80.
89. Davis JS, Mackrow C, Binks P, et al. A double-blind randomized controlled trial of ibuprofen compared to placebo for uncomplicated cellulitis of the upper or lower limb. Clin Microbiol Infect 2017;23:242–6.
90. Bergkvist PI, Sjöbeck K. Antibiotic and prednisolone therapy of erysipelas: a randomized, double blind, placebo-controlled study. Scand J Infect Dis 1997;29:377–82.
91. Bergkvist PI, Sjöbeck K. Relapse of erysipelas following treatment with prednisolone or placebo in addition to antibiotics: a 1-year follow-up. Scand J Infect Dis 1998;30:206–7.

ARTICLE SUMMARY

1. Why is this topic important?

Skin and soft tissue infections, such as cellulitis and abscess, are common conditions requiring care in the emergency department.

2. What does this review attempt to show?

This review provides an evidence-based summary of the background, pathophysiology, diagnosis, and management of cellulitis and abscesses for emergency clinicians.

3. What are the key findings?

Staphylococcus aureus, Streptococcus pyogenes, and other β-hemolytic streptococci are the most common causes of cellulitis, and methicillin-resistant *S. aureus* is most common in abscesses. History and physical examination can assist clinicians, and point-of-care ultrasound can differentiate unclear cases. Treatment for cellulitis typically involves a penicillin or cephalosporin, and treatment for abscesses is incision and drainage. Loop drainage is preferred over the traditional incision and drainage technique, and adjunctive antibiotics can be considered. Most patients can be managed as outpatient.

4. How is patient care impacted?

An understanding of recent literature updates concerning cellulitis and abscess can assist emergency clinicians.